

Harnessing Light and Energy for the Early Detection of Dental Caries

Stephen Abrams, DDS

The detection and treatment of dental caries has not changed radically since the time of G. V. Black. Detection of caries depended upon locating mineral loss on bite wing radiographs, examining stain and discoloured areas on the tooth surface or probing lesions with a sharp explorer. All these techniques depended upon the interaction of two parts of the electromagnetic spectrum; visible light or x-rays. Radiographs and visual examination can detect caries but at a much later stage in the disease process so treatment involves operative techniques to restore tooth structure that has been destroyed. Restorations have become more conservative with the introduction of bonding but detection and treatment is done once the lesion is fairly large. There are a number of new technologies that can locate and monitor early small carious lesions using different forms of light or energy. When one combines early detection with new technologies for remineralization we can treat, stabilize or remineralize carious lesions without the need for surgical intervention.

These diagnostic techniques focus light or energy on a tooth surface and examine the interaction with tooth structure. The interactions are classified in figure 1 from work published by Hall and Girkin in 2004.¹ X-Rays involve both transmission and scattering. The scattering occurs when they encounter calcified tissue and restorations. Visual examination is looking at reflection of light from the

tooth surface along with some backscattering from areas just below the surface. The newer technologies are combinations of these various phenomena including fluorescence, absorption with heat production etc.

There are a number of other factors that influence the sensitivity of the detection system such as the wavelength of light, the resolution and sensitivity of the detection system and the distance of the detector from the tooth surface. Longer wavelengths will penetrate deep into tooth structure but may miss small areas of decay. One needs to consider all these factors when harnessing light and energy for caries detection. The final consideration is the location being studied and the presence of existing restorations. Early interproximal lesions and caries around restorations present major challenges for any diagnostic system.

WHAT IS DENTAL CARIES?

Dental caries arises from an overgrowth of specific bacteria that can metabolize fermentable carbohydrates and generate acids as waste products of their metabolism. Streptococci mutans and Lactobacillus are the two principal species of bacteria involved in dental caries and are found in the plaque biofilm on the tooth surface.^{2,3,4} When these bacteria produce acids, the acids diffuse into tooth enamel, cementum or dentin and dissolve or partially dissolve the mineral from crystals

below the surface of the tooth. If the mineral dissolution is not halted or reversed, the early subsurface lesion becomes a "cavity".

The tooth surface undergoes demineralization and remineralization continuously, with some reversibility. When exposed to acids, the hydroxyapatite crystals dissolve to release calcium and phosphate into the solution between the crystals. These ions diffuse out of the tooth leading to the formation of the initial carious lesion. The reversal of this process is remineralization. Remineralization will occur if the acid in the plaque is buffered by saliva, allowing calcium and phosphate present primarily in saliva to flow back into the tooth and form new mineral on the partially dissolved subsurface crystal remnants.⁵ The new "veneer" on the surface of the crystal is much more resistant to subsequent acid attack, especially if it is formed in the presence of sufficient fluoride. The balance between demineralization and remineralization is determined by a number of factors. Featherstone describes this as the "Caries Balance", or the balance between protective and pathological factors (see figure 2).⁶

These early lesions (both enamel and root surface) typically have an intact hard outer surface with subsurface demineralization. The tooth surface remains intact because remineralization occurs preferentially at the surface due to increased levels of calcium and phosphate ions. Figure 3⁷ shows a

cross-section of an early carious lesion using polarising light microscopy. The line drawing in Figure 4 shows the various layers in an early lesion.⁸ The clinical characteristics of these early carious lesions include:

- Loss of normal translucency of the enamel resulting in a chalky white appearance particularly when dehydrated,
- Fragile surface layer susceptible to damage from probing, particularly in the pits and fissures,
- Increased porosity, particularly of the subsurface, with increased potential for uptake of stain,
- Reduced density of the subsurface, which may be detectable radiographically (depending upon mineral loss and location) or with transillumination (depending upon location and loss of mineral),
- Potential for remineralization with increased resistance to further acid challenge particularly with the use of enhanced remineralization treatments.⁹

RADIOGRAPHIC AND VISUAL DETECTION OF CARIES

Radiographic and visual examination are satisfactory if there is a substantial cavitated carious lesion. Detecting early pit and fissure caries is challenging.

Radiographic imaging is of minimal diagnostic value because of the large amounts of surrounding enamel.^{10,11} A number of studies have found the dental explorer inefficient for the diagnosis of occlusal caries.^{12,13} There are a number of the concerns with the use of the explorer in detecting pit and fissure caries:

- Since cavitation in pit and fissure caries occurs late in the disease process, using an explorer stick to detect caries only finds larger lesions,
- Probing an occlusal pit or fissure could convert a small lesion into a larger one,¹⁴
- The probing could produce irreversible traumatic defects in areas that have the potential to remineralize,
- Probing can inoculate the fissure with microorganisms from other intraoral sites,^{15,16}
- A stick or catch with an explorer may be due to fissure morphology or probe pressure rather than a carious lesion.

Radiographs do perform well in detecting carious lesions in interproximal areas, especially if the area of decay is at least half way through the enamel or into dentin. In terms of early lesion detection, radiographs are not able to detect

small lesions in the order of 50 - 100 μ (microns) in the interproximal areas, which could remineralize if detected early and suitable preventive measures instituted.¹⁷ An extensive review of the literature by Dove¹⁸ found that “overall the strength of the evidence for radiographic methods for the detection of dental caries is poor for all types of lesion on proximal and occlusal surfaces”. He further stated that “it is beneficial only if the intervention is the surgical removal of tooth structure and detrimental if it is used for non-invasive remineralization methods”. Pretty and Maupome in their review of radiographic diagnostic procedures concluded that “for interproximal lesions a clinician using radiographs can be very certain of the lack of disease in apparently sound surfaces (97% specificity) but not as certain that disease is indeed present in suspect interproximal surfaces (54% sensitivity)”.¹⁹ Radiographs and visual examination are valid diagnostic tool for the detection of larger lesions but there is need for more sensitive methods.

DIAGNODENT

DIAGNODent^{20,21} uses laser excitation to distinguish between carious and healthy tooth structure. The device is based upon the

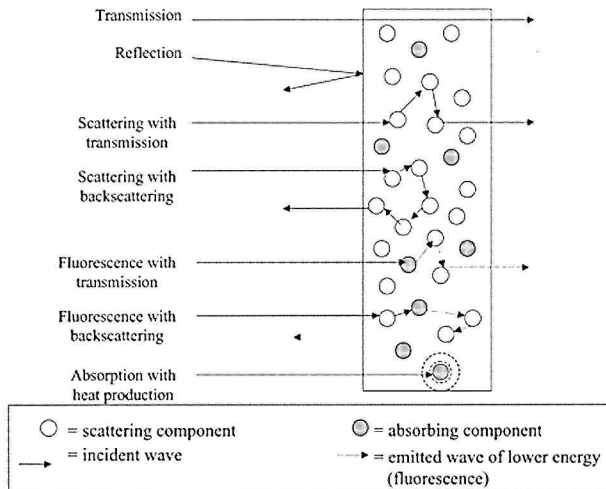


FIGURE 1— Interaction of light with tooth.

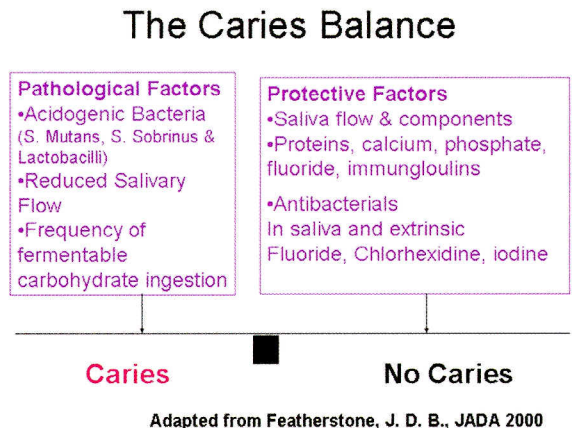


FIGURE 2—The caries balance.

fluorescence caused by porphyrins (chromophores or coloured protein molecules) present in carious tissue and not the amount of enamel demineralization.²² Porphyrins are also found in a number of oral bacteria but not the prime bacteria found in dental caries (*Strep mutans* and *Lactobacilli*).²³ Porphyrin fluorescence can lead to false positives since porphyrins are also found in stained, healthy fissures.^{24,25} A number of studies have been performed to assess the feasibility of using this device,^{26,27} and they have concluded there is potential to improve occlusal caries assessment compared to visual examination and radiographs. Nevertheless, a validity study involving the DIAGNodent concluded that it was not statistically significantly different from visual inspection.²⁸ DIAGNodent is suitable for detecting small superficial lesions, rather than deep dentinal lesions.²⁹ There are various sensitivity and specificity values obtained for the DIAGNodent and they differ widely among different researchers, 0.76 ~ 1.00 for the sensitivity and 0.47 ~ 0.94 for the specificity.^{30,31,32,33,34}

Ongoing research discovered that certain dental polishing pastes that became trapped in the occlusal grooves also luminesced when exposed to the DIAGNodent light creating a false positive signal³⁵ In addition, plaque, calculus and composites also created a false signal.³⁶

Work just published by Karlson and others found that DIAGNodent is not suitable as a diagnostic tool for root caries, a common problem in older patients.³⁷ Fluorescence especially at this particular wavelength may not provide the most accurate tool for early caries diagnosis since it is monitoring porphyrin fluorescence and is not linked to the status of the enamel crystal.

QLF (QUANTITATIVE LIGHT-INDUCED FLUORESCENCE)

QLF or Quantitative Light-Induced Fluorescence was developed by Inspektor Research in the Netherlands and is now distributed in North America by 3M. With QLF, real-time fluorescent images are captured into the computer and stored in an image database. Proprietary software developed by Inspektor Research enables the user to quantify parameters like mineral loss, lesion size, stain size and severity with precision and repeatability. Several studies have demonstrated the ability of the QLF system to detect and monitor caries over time, both in children and adults.^{38,39,40} The principle behind it relies on the fact that the enamel surface will fluoresce under certain optical excitation conditions.⁴¹ If the enamel is demineralized, the enamel fluoresces less and this loss of fluorescence is detected and quantified by QLF.^{42,43}

QLF is more accurate than visual examination⁴⁴ or radiographs, DIAGNodent or DIFOTI.⁴⁵ QLF

is very promising but there is need to develop the capability to probe lesion depths. It may not be able to detect interproximal lesions deep within the contact area. QLF has also been adopted by other manufacturers but it may not be as sensitive as the Inspektor Research version due to differences in software analysis and image capture technology. QLF examines the changes in fluorescent images of a tooth surface and is able to provide an accurate assessment of changes in mineral content of the tooth.⁴⁶

CARIES ID

The Caries ID from Midwest detects reflected infra-red and red light from the tooth surface. Using an incident beam from an LED, the device measures the reflectance. Healthy enamel is more translucent than demineralized enamel so the device is able to measure and quantify the change in reflectance. Caries ID is able to detect early caries on smooth surfaces, interproximal areas and occlusal fissures. There may be false positives associated with the following conditions:⁴⁷

- teeth with growth malformations in enamel or dentin such as amelogenesis imperfecta
- teeth with dark stains
- hypermineralization
- hypocalcification
- dental fluorosis

The Caries ID may generate false positives in these situations:^{48,49}

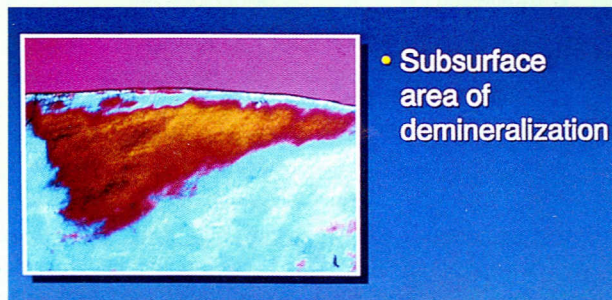


FIGURE 3—Early demineralization lesions from Crest.

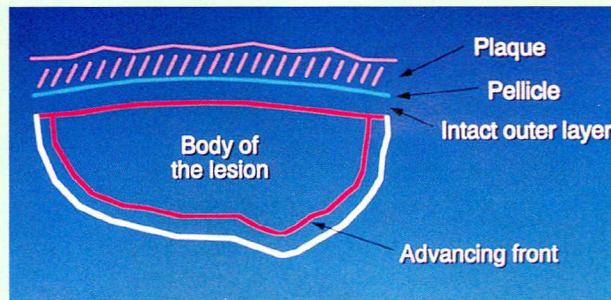


FIGURE 4—Early demineralization lesions from Crest line drawing.

- on or at the interface of dental restorations or for residual drilling caries detection
- on buccal and lingual areas of anterior and posterior teeth
- on dark brown stains, calculus and intense plaque,
- on restorations and sealants
- on primary teeth due to thin enamel
- if there is very intense ambient light
- on dry teeth.

Since the technology is based upon reflectance and not luminescence the device cannot detect lesions below the surface and can be fooled by dark stain and surface topography. The technology was just introduced in 2006 with very little published background research initially. Caries ID may be more accurate than visual or radiographic examination for pit and fissure caries but it has a number of limitations and can not be used to assess ongoing remineralization or demineralization.

THE CANARY SYSTEM (PTR-LUM)

The Canary System developed by Quantum Dental Technologies takes a different approach to light interacting with teeth. The Canary, using the same type of near Infra-Red laser as DIAGNODent or Caries ID, rapidly pulses the laser and looks at the interaction of the laser light when the laser is turned off.

When pulses of laser light are focused on a tooth, the tooth glows and releases heat. The analysis of the re-emitted radiation (luminescence) and the thermal behavior of the emitted infrared photons, provides very accurate information about the condition of the tooth. As a lesion grows, there is a corresponding change in the signal. As remineralization progresses, a signal reversal indicates an improvement in the condition of the tooth. The temperature rise in the tooth is no more than 1-2 degrees Celsius which patients can not detect. There is no alteration of any of the tissues and no safety issues such as those associated with dental x-rays.

The Canary System is able to see down about 4-5 millimetres (the average depth of tooth enamel), by changing the cycle or frequency of the laser pulse. Low frequencies about 5 Hertz, are deep probes because the heat that is generated pulses up and down very slowly and so it penetrates very deeply into the tooth. High frequencies, around 1,000 Hertz are shallow probes.

Research has shown that PTR-LUM technology used in The Canary System can detect:

- Occlusal Pit and fissure caries 50,51,52
- Smooth Surface Caries^{53,54}

- Acid Erosion Lesions⁵⁵
- Root Caries^{56,57}
- Interproximal carious lesions^{58,59}

Demineralization and Remineralization of early carious lesions⁶⁰

PTR-LUM has demonstrated that it is able to detect small early lesions in order of 50 microns in depth, even in the interproximal regions of teeth. The Canary System is currently undergoing clinical trials which should be completed by the time this article is published.

DETECTING SECONDARY CARIES AROUND RESTORATIONS

This is one of the most challenging clinical situations for all these new technologies. Restorative materials including amalgam and composite resin, at times, mask the ability of laser light or other forms of energy to penetrate the material. Radiographs can show us defects along the gingival seats of Class II restorations but they cannot examine the walls of the restorations nor the occlusal surfaces. DIAGNODent, D-Carie and QLF have problems with caries detection although QLF is able to monitor the margins of composites and sealants on the occlusal, buccal and lingual surfaces. The Canary System using PTR-LUM has shown in preliminary studies

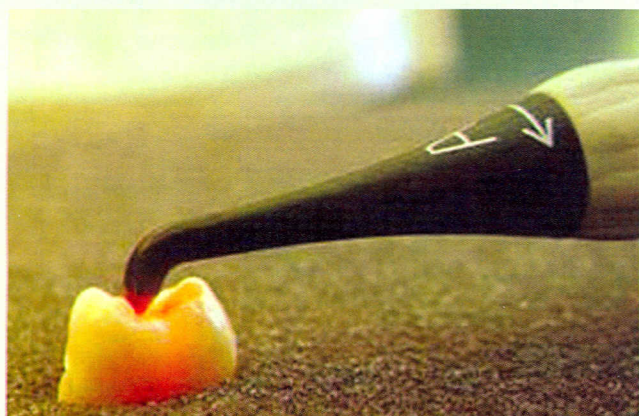

FIGURE 5—DIAGNODent on tooth.




FIGURE 6—QLF showing computer and monitor.

the ability to detect lesions around the visible margins of composites.⁶¹

SUMMARY

Light, energy and teeth allow for some very interesting interactions. Using low power lasers, x-rays, visible light and other modalities we can explore and detect caries and other defects in teeth. Each modality has its strengths and weaknesses but the new and emerging technologies will allow clinicians to non-invasively detect and monitor tooth decay. Developing sensitive monitoring systems means we can create unique remineralization programs for our patients and change the way we treat dental caries. Waiting for cavitation may not be optimal treatment. Early detection and remineralization will emerge as the standard approach to treating dental caries. **OH**

Disclosure

Dr. Stephen Abrams is CEO of Quantum Dental Technologies, which has developed The Canary Dental Caries Detection System. He has not received any compensation for the preparation of this article.

Stephen Abrams is the founder of Four Cell Consulting, Toronto Ontario, Canada, which provides consulting services to dental companies in the area of new product development and promotions. Dr. Abrams recently founded Quantum Dental Technologies, a company developing laser-based technology for the early detection and ongoing monitoring of dental caries. He developed the "Triple Laminate Technique" for utilizing soft tissue undercuts when fabricating complete and partial dentures. Dr. Abrams was awarded the Barnabus Day Award from the Ontario Dental Association for 20 years of distinguished service to the dental profession. He is one of the founding board members of ACCERTA Claim Corporations, a dental and pharmacy claims management company. He can be contacted at (416)-265-1400 or e mail; dr.abrams4cell@sympatico.ca

Oral Health welcomes this original article.

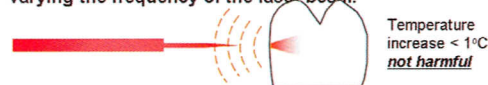
REFERENCES

- Hall, A., Girkin, J., "A Review of Potential New Diagnostic Modalities for Caries Lesions", J. Dent. Res., 2004; 83 (Special Issue C): C89 - C94
- Van Houte, J., "Bacterial specificity in the etiology of dental caries", Int. Dent. J., 1980; 30: 305 - 326
- Van Houte, J., "Role of Microorganism in the caries etiology", J. Dent. Res., 1994; 73: 672- 681
- Featherstone, J. D. B., "The Caries Balance: Contributing Factors and Early Detection", CDA Journal, 2003; 13 (2): 129 - 133
- Melberg, J. R., "Remineralization: A status report for the American Journal of Dentistry, Part 1, Am J. Dent., 1988; 1 (1): 39 - 43
- Featherstone, J. D. B., "The Science and Practice of Caries Prevention", JADA, 2000; 131: 887 - 899
- Proctor & Gamble "Deminerlization - Remineralization" Slide Series, 2005
- Proctor & Gamble "Deminerlization - Remineralization" Slide Series, 2005
- Mount, G. J., "Defining, Classifying, and Placing Incipient Caries Lesions in Perspective", Dent Clin N. Am, 2005, Volume 49, pages 701 - 723

- McKnight-Hanes C, Myers DR, Dushku JC, Thompson WO, Durham LC. "Radiographic recommendations for the primary dentition: comparison of general dentists and pediatric dentists". *Pediatr Dent.* 1990 Jul-Aug;12(4):212-216
- Flaitz CM, Hicks MJ, Silverston LM. Radiographic, histologic, and electronic comparison of basic mode videoprints with bitewing radiography. *Caries Res.* 1993; 27(1): 65-70.
- Penning C, van Amerongen JP, et al, "Validity of probing for fissure caries diagnosis". *Caries Res* 26:445-9, 1992
- Lussi A, "Comparison of different methods for the diagnosis of fissure caries without cavitation". *Caries Res* 27:409-16, 1993
- Yassin OM. In vitro studies of the effect of a dental explorer on the formation of an artificial carious lesion." *ASDC J Dent Child.* 1995 Mar-Apr;62(2):111-117
- Ekstrand K, Qvist V, Thylstrup, A, "Light microscopic study of the effect of probing in occlusal surfaces"., *Caries Research*, 1987; 21: 368 - 374
- Penning C, Van Amerongen JP, Seef RE, ten Cate, JM "Validity of probing for fissure caries diagnosis", *Caries Research*, 1992; 26(6): 445 - 449
- Backer DO, "Post-eruptive changes in dental enamel", *J Dent Res* 1966; 45: 503 - 51
- Dove, S. B., "Radiographic Diagnosis of Dental Caries in Consensus Conference on Dental Caries Management Throughout Life, March 2001, Journal of Dental Education, 2001; 65 (10): 985 - 990
- Pretty, I. A., Maupome, G., "A Closer Look at Diagnosis in Clinical Dental Practice: Part 3. Effectiveness of Radiographic Diagnostic Procedures", *JCDA*, 2004; 70(6): 388 - 394
- Hibst R, Konig K: "Device for Detecting Dental Caries". US Pat 1994; 5,306,144

See Abrams page 42

- Pulses of laser light in a range of on-off frequencies hit the tooth surface .
- The tooth glows (Luminescence, LUM) and releases heat (Photo-Thermal Radiometry, PTR) at those same frequencies.
- PTR can provide a depth profile of tooth properties by varying the frequency of the laser beam.



- The detected LUM and PTR signals reflect the tooth's condition at and below the surface.

FIGURE 7—The science behind the Canary System.

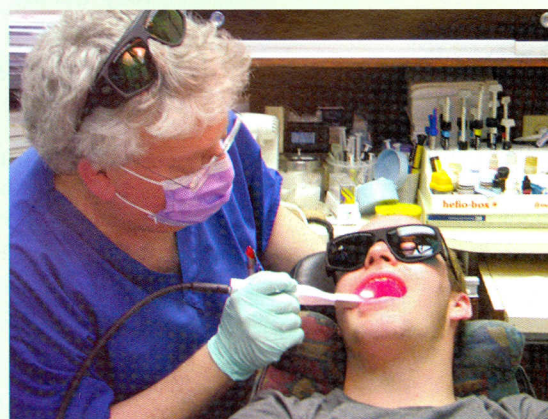

FIGURE 8—The Canary in clinical use.

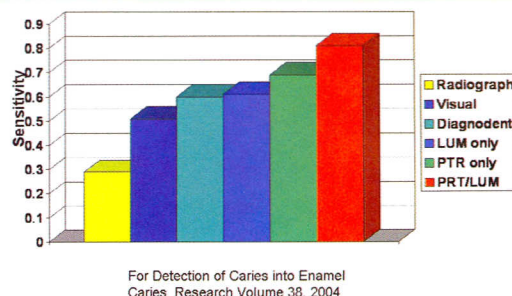


FIGURE 9—Sensitivity of early caries detection methods relative to PTR-LUM.

Need a Break?

Join the Veisman Institute of Periodontology Continuing Education Travel Series:

Herbie Goes To.....

Miami, Florida

Dec. 24 to 25, 2009,
 Tulee City Fairmont Hotel

Cayman Islands,

Feb. 13th to 20th, 2010,
 Ritz Carlton Hotel

Miami, Florida,

Mar. 11th to 18th, 2010,
 Ritz Carlton Key Biscayne Hotel


Los Angeles, California,

July 31st to Aug. 14th 2010,
 TBA

Honolulu, Hawaii,

Oct. 29th, to Nov. 12th, 2010,
 TBA

If you want great rates at *Leading Hotels of the World, Relais and Chateaux* and you wish to dine at *Red Star Michelin Restaurants* while earning CE credits, this is the one and only course of its kind in the world.



Dr Herbert Veisman
 Periodontics Asleep™,
 including Implant Dentistry
 Nestle Tower

1005-25 Sheppard Ave West
 Toronto ON CANADA. M2N 6S6
 416-225-9910 or 1-(866)-4-PERIO-4
 drveisman@torontoimplant.com

www.torontoimplant.com

Abrams continued from page 16

21. Hibst R, Gall R and Klafke M: "Device for the Recognition of Caries, Plaque or Bacterial Infection on Teeth". US Pat 2000; 6,024,562
22. Alwas-Danowska HM, Plasschaert AJM, Suliborski S and Verdonschot EH: "Reliability and validity issues of laser fluorescence measurements in occlusal caries diagnosis". J Dentistry 2002; 30: 129 - 134
23. Konig, K., Hibst, R., et al., "Laser - induced autofluorescence of carious regions of human teeth and caries-involved bacteria", SPIE, 1993: 2080: 170 - 180
24. Hibst R, Paulus R: "Caries detection by red excited fluorescence: Investigations on fluorophores". Caries Res 1999;33:295.
25. Welsh GA, Hall AF, Hannah AJ, Foye RH: "Variation in DIAGNOdent Measurements of Stained Artificial Caries Lesions". Caries Res 2000; 34: 324
26. Shi XQ, Welander U, and Angmar- Månsson B: "Occlusal Caries Detection with KaVo DIAGNOdent and Radiography: An in vitro Comparison". Caries Res 2000;34:151-158
27. Shi XQ, TranĖus S, and Angmar- Månsson B: "Comparison of QLF and DIAGNOdent for Quantification of Smooth Surface Caries". Caries Res 2001; 35: 21-26
28. Alwas-Danowska HM, Plasschaert AJM, Suliborski S and Verdonschot EH: "Reliability and validity issues of laser fluorescence measurements in occlusal caries diagnosis". J Dentistry 2002; 30: 129 - 134
29. Alwas-Danowska HM, Plasschaert AJM, Suliborski S and Verdonschot EH: "Reliability and validity issues of laser fluorescence measurements in occlusal caries diagnosis." J Dentistry 2002; 30: 129 - 134
30. Lussi A, Imwinkelried S, Pitts NB, Longbottom C, and Reich E: "Performance and Reproducibility of a Laser Fluorescence System for Detection of Occlusal Caries in vitro." Caries Res 1999; 33: 261-266
31. Lussi A, Megert B, Longbottom C, Reigh E, Francescut P: "Clinical performance of a laser fluorescence device for detection of occlusal caries lesions". Eur J Oral Sci 2001;109: 14-19
32. Heinrich-Weltzien R, Weerheijm KL, KĖhnisch J, Oehme T and StĖsser L: " Clinical evaluation of visual, radiographic, and laser fluorescence methods for detection of occlusal caries." J Dent Child 2002; 69: 127-132
33. Costa AM, Yamaguchi PM, De Paula LM and Bezerra ACM: "In vitro study of laser diode 655 nm diagnosis of occlusal caries." J Dent Child 2002; 69: 249-253
34. Anttonen V, SeppĖ L and Hausen H: "Clinical Study of the Use of the Laser Fluorescence Device DIAGNOdent for Detection of Occlusal Caries in Children." Caries Res 2003; 37: 17-23
35. Hosoya Y, Matsuzaka A, Inoue T, "Influence of tooth polishing pastes and sealants on DIAGNOdent Values", International Congress Series 1248 2003; 183 - 185
36. Hibst R, Paulus R, Lussi A, "Detection of occlusal caries by laser fluorescence: Basic and Clinical Investigations", Med Laser Appl. 2001; 16: 205 - 213
37. Karlsson, I., Johansson, E., Tranaeus, S., "Validity and Reliability of Laser-Induced Fluorescence Measurements on Carious Root Surfaces in vitro", Caries Research, 2009; 43: 397 - 404
38. Amaechi BT, Higham SM. Quantitative Light-Induced Fluorescence: a potential tool for general dental assessment. Journal of Biomedical Optics 7(1); 7-13: 2002
39. Amaechi BT, Higham SM. Diagnosis of dental caries using Quantitative Light-induced Fluorescence. In: Diagnostic Optical Spectroscopy in Biomedicine. T. Papazoglou, G. A. Wagnieres (Editors), Proceedings of SPIE 2001; 4432: 110-117
40. Amaechi BT, Higham SM. Longitudinal Assessment of Dental Caries Using Quantitative Light-Induced Fluorescence. Caries Research 2001; 35: 269 (abst. 14)
41. Stookey, G., "Quantitative Light Fluorescence: A Technology for Early Monitoring of the Caries Process", Dent. Clin. N. Am., 2005; 49: 753 - 770
42. van der Veen, M. H. and E. de Josselin de Jong (2000). " Monogr Oral Sci 17: 144-62. Application of quantitative light-induced fluorescence for assessing early caries lesions
43. Pretty, I. A., W. M. Edgar, et al. (2002). "Detection of in vitro demineralization of primary teeth using quantitative light-induced fluorescence (QLF)." Int J Paediatr Dent 12(3): 158-67
44. Kuhnisch, J., Ifland, S., Tranaeus, S. et al., "In vivo Detection of Non-Cavitated Caries Lesions on Occlusal Surfaces by Visual Inspection and Quantitative Light-Induce Fluorescence", Acta Odontologica Scandinavica, 2007; 65: 183 - 188
45. Ferreira, Z., Ando, AG, Eggertsson, H., et al., "Clinical Validation of Caries Detection Methodologies: Preliminary Results", J. Dent. Res., 2004; 83 (Special Issue A), 2812a
46. De Josselin de Jong, E., Higham, S. J., Smith, P. W., van Daelen, C. J., van der Veen, M., "Quantitative Light-Induced Fluorescence, A Review of a Diagnostic Tool in Prevention of Oral Disease". J Applied Physics, 2009; 105: 102031 1 - 7
47. D-Caries Mini Instruction Manual, NEKS Technology 2006
48. D-Caries Mini Instruction Manual, NEKS Technology 2006
49. Caries ID Instruction Manual Midwest 2008
50. Jeon, R. J., Han, C., Mandelis, A., Sanchez, V., Abrams, S. H., "Dental Depth Profilometric Diagnosis of Pit & Fissure Caries using Frequency-Domain Infrared Photothermal Radiometry and Modulated Laser Luminescence", Early Detection of Caries III Proceedings of the Sixth Indiana Conference Indiana University School of Dentistry, pages 49 - 67, Stookey, G., editor, 2003
51. Jeon, R. J., Han, C., Mandelis, A., Sanchez, V., Abrams, S. H., "Diagnosis of Pit & Fissure Caries using Frequency-Domain Infrared Photothermal Radiometry and Modulated Laser Luminescence" Caries Research 2004 Volume 38, pages 497- 513
52. R. Jeon, A. Mandelis and S. Abrams, "Dental depth profilometric diagnosis of pit and fissure caries using frequency-domain infrared photothermal radiometry and modulated luminescence", SPIE Vol. 5320, Photons plus Ultrasound: Imaging and Sensing (A. A. Oraevsky and L. V. Wang, Eds., Bellingham WA 2004, pp. 29 39
53. Jeon, R. J., Han, C., Mandelis, A., Sanchez, V., Abrams, S. H., "Non-intrusive, Non-contacting Frequency-Domain Photothermal Radiometry and Luminescence Depth Profilometry of Carious and Artificial Sub-surface Lesions in Human Teeth," Journal of Biomedical Optics 2004, July - August ,9, # 4, 809 - 819.
54. Jeon, R. J., Mandelis, A., Abrams, S. H., "Depth profilometric case studies in caries diagnostics of human teeth using modulated laser radiometry and luminescence", Review of Scientific Instruments, 2003, January, Volume 74 # 1, pages 380 - 383
55. Jeon R. J., Phan T. D. T., Wu A., Kulkarni G., Abrams S. H., and Mandelis A., "Photothermal radiometric quantitative detection of the different degrees of demineralization of dental enamel by acid etching," J. Physique IV France, 2005 125, 721 - 72
56. Jeon, R. J. Hellen, A., Matvienko, A., Mandelis, A., Abrams, S. H., Amaechi, B. T., "Detection of Demineralized-Remineralized Lesions on Root and Enamel of Human Teeth in vitro using Infrared Photothermal Radiometry and Modulated Luminescence", ORCA Abstract # 157, Caries Research 2007, 41:323
57. Jeon R. J., Hellen A., Matvienko A., Mandelis A., Abrams S. H., Amaechi B. T., "In vitro Detection and Quantification of Enamel and Root Caries Using Infrared Photothermal Radiometry and Modulated Luminescence." Journal of Biomedical Optics, 2008; 13(3), 048803
58. Jeon R.J., Matvienko A., Mandelis A., Abrams S.H., Amaechi B.T., Kulkarni G. "Detection of interproximal demineralized lesions on human teeth in vitro using frequency-domain infrared photothermal radiometry and modulated luminescence", J. BioMed. Optics, 2007; 12(3); 034028 1 - 13.
59. Jeon, R. J., Matvienko, A., Mandelis, A., Abrams, S. H., Amaechi, B. T., Kulkarni, G., "Interproximal Dental Caries Detection using Photothermal Radiometry (PTR) and Modulated Luminescence (LUM)", European Physical Journal, Special Topics, 2008, 153: 467 - 469.
60. Jeon, R. J. Hellen, A., Matvienko, A., Mandelis, A., Abrams, S. H., Amaechi, B. T., "Detection of Demineralized-Remineralized Lesions on Root and Enamel of Human Teeth in vitro using Infrared Photothermal Radiometry and Modulated Luminescence", ORCA Abstract # 157, Caries Research 2007, 41:323.
61. Hellen, A., Jeon, R., Abrams, S. H., Mandelis, A., Amaechi, B. T., "Photothermal and Modulated Luminescence Detection of Demineralized Tooth Restoration Interfaces", Abstract # 529, IADR , 2008.